



PIG TALES



ON-FARM POST MORTEMS

Written by Liz Bennett

All of you are aware of the nightmare when checking your pigs first thing in the morning and you are faced with an animal that has died overnight; worse still when it is a pig that has been showing no previous ill effects or signs. What if there's more than one? Do you just put it down to 'one of those things' and chuck it in the incinerator?

If you are faced with this situation it is advisable to call us out for a post-mortem examination. Even if we find that the cause of death is a 'one-off' that will have no consequences for the rest of the herd, it will help to put your mind at rest.

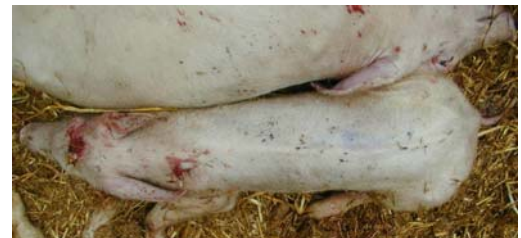If you do decide to ask for a post-mortem, it is important that we are called quickly, because decomposition can occur rapidly in pigs. Often gross examination alone can provide a provisional diagnosis, but sometimes we may need to take samples to send to the lab to confirm this. Reaching a prompt diagnosis will lead to early treatment and can sometimes prevent a disease spreading through your unit with possible serious consequences.

If there are no recently dead animals available for post-mortem, it is often cost effective to put down a sick pig so that we can carry out the post mortem as fresh as possible, to give us the best chances of obtaining relevant samples.



It is very important we are informed of any relevant history:

- What is the age of the animal?
- What pen did it come out of?
- How many pigs were in the group/in direct contact?
- How many other pigs have died?
- Did this pig have any clinical signs prior to death?
- Are any of the rest of the pigs showing any signs?
- Are they receiving any medication? In feed/water/by injection?
- What diseases are known to be on your unit? What do you vaccinate against?
- Have there been any recent environmental changes?
 - a recent move
 - a change of feed
 - a broken drinker
 - a failure in temperature control/ventilation



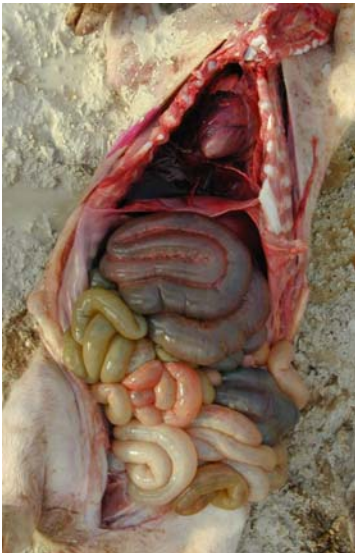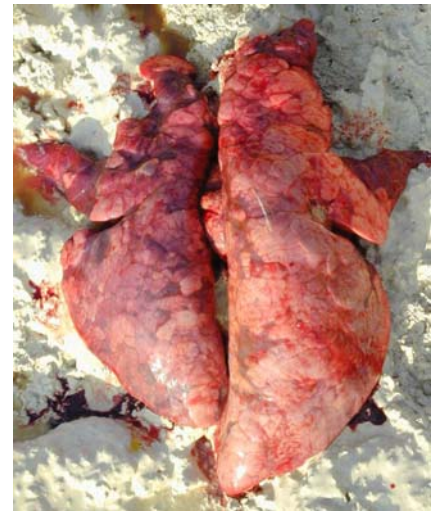This clinical history may indicate which organ system is likely to be involved, but it is important that we follow a standardised systematic approach to a post-mortem, so that the body as a whole is thoroughly examined. If this systematic approach is not followed, it can be easy to miss things. You will notice that different vets may have their own techniques, but all will follow a set pattern.

A PM requires nothing more than a sharp knife (or scalpel), a saw (depending on size of the pig) and protective clothing (waterproofs or apron, gloves and boots). Scissors and forceps are useful but not essential. If a table and access to water are not available, then performing the PM on an opened feed sack will assist in keeping the area as clean as possible.

Some diseases are very easy to pick up on a post mortem :-

Enzootic pneumonia - obvious consolidated areas (darker heavier pink areas), which tend to be at the lung lobe tips. These can be scored out of 55 to give an EP score. You may recognise these figures from the BPEX/BPHS abattoir monitoring scheme.

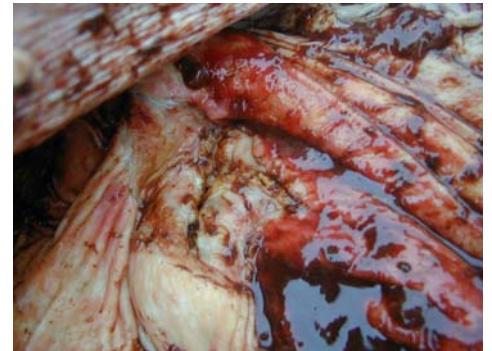
Glassers disease - a fibrinous pleurisy, pericarditis and/or peritonitis. Milder forms of this can also be caused by streptococcal meningitis.



Haemorrhagic enteritis (bloody guts) - Seen as very red inflamed intestines, the contents of which may be blood tinged, there are several causes for this and samples often need to be taken.

Stomach Ulcers - Seen as a blood filled stomach, often caused by stress or sudden feed changes.

PDNS/PMWS - There may be obvious skin lesions that many of you will recognise; internally signs you may see are spotty enlarged kidneys, swollen lungs and enlarged bloody lymph nodes.



There are occasions when you can get useful material from pigs found dead without calling us out for a full post-mortem. The most useful is in the farrowing area when you are faced with dead piglets. Often, you cannot be sure whether these were born dead, or born alive then died subsequently. A simple PM can usually answer this question.

Open the carcass with a long incision from throat to groin, then open up the chest cavity and remove the lungs. If you place the lungs in a bucket of water and they float then this suggests that they contain air, which can only be the case if the pig had taken a breath (in other words they must have been born alive). If they sink, then that piglet had never breathed and was almost certainly stillborn.

If there is a large amount of blood in the abdominal cavity, then this usually is the result of a rupture of a major vessel or organ, such as the liver, which is a good indication that the pig was overlaid.

A dead pig thrown away is such a waste of useful information that could be used to protect your herd. Remember this the next time you find a dead pig. Call us at the surgery if you want to discuss anything further. We can be reached on 01491 651479.

